

Varicella zoster virus

Monica L. McCrary, MD,^a Jessica Severson, MD,^b and Stephen K. Tyring, MD, PhD^b
Augusta, Georgia, and Galveston, Texas

Because of its ability to produce two clinically distinct disease entities (chickenpox and shingles), varicella zoster virus (VZV) is an unusual etiologic agent. Although in the past viral exanthems were mostly only of academic interest to the practitioner, the development of antiviral agents and the newly approved varicella (OKA) vaccine have increased the clinical significance. Also, with the increasing seroprevalence of HIV infection, more patients will be stricken with zoster (at a younger age) and disseminated varicella. In this review, the history, incidence, pathogenesis, clinical manifestations, and treatment options (of VZV infection and postherpetic neuralgia) will be discussed. (*J Am Acad Dermatol* 1999;41:1-14.)

Learning objective: At the completion of this learning activity, participants should be able to discuss the history, incidence, pathogenesis, clinical manifestations, and treatment options for both VZV infection and PHN.

Varicella zoster virus (VZV) is a unique herpes virus in that it is capable of producing two different syndromes, varicella (chickenpox) and herpes zoster (shingles). It belongs to the subfamily Alphaherpesvirinae¹ (along with herpes simplex virus [HSV] types 1 and 2) and, like these, is a double-stranded DNA virus. Containing the smallest genome of the herpesviruses, it is an enveloped icosahedral virus approximately 200 nm in diameter.

HISTORY

In 1767, Heberden was able to clearly distinguish chickenpox from smallpox.² It is believed that the word "chickenpox" either comes from the Old English word "gican" meaning "to itch"³ or alternately, from the old French word "chiche-pois" for chickpea, thought to describe the size of the vesicle.⁴ The association between chickenpox and shingles was first noticed by von Bokay in 1888. He noted that chickenpox sometimes developed in susceptible children after exposure to persons with acute shingles.⁵ The next development was made when Kundratiz was able to produce varicella-like lesions and generalized varicella in children by inoculation

with vesicle fluid from patients with zoster.⁶ This relationship was finally confirmed in 1952 by Weller and Stoddard,⁷ who were able to show that identical viruses were recovered from patients with chickenpox and shingles using *in vitro* studies.

INCIDENCE

Primarily a disease of childhood (90% of cases occur in children younger than 10 years of age), varicella is a disease that has historically touched a large majority of the population, with 95% of parturient women in New York City⁸ and 95% of HIV-positive men⁹ showing serologic evidence of infection. Another study showed a nearly 99% rate of immunity to varicella.¹⁰ Finally, among military recruits (mostly from ages 17 to 19 years) the seronegativity rate was found to be 8.2%.¹¹ In fact, a study of pregnant patients with negative or indeterminate history of varicella-like illness demonstrated that 81% will show serologic evidence of subclinical infection.¹² In the study of military recruits, however, although the positive predictive value of a history of varicella was high (>95%), almost all recruits gave a positive history of varicella, even those (<20%) lacking the antibody.¹¹ Rarely reported recurrences of varicella are probably a result of misdiagnosis (eg, coxsackievirus infection).¹³

Although chickenpox is a disease of children, shingles occurs primarily in adults older than 50 years, although it can occur at any age. By decades, the incidence is 2.5/1000 persons affected per annum between the ages of 20 and 50 years, 5.09/1000 persons per annum for the ages of 51 to 79

From the Section of Dermatology, Medical College of Georgia, Augusta,^a and the Departments of Dermatology, Microbiology/Immunology and Internal Medicine, University of Texas Medical Branch, Galveston.^b

Reprint requests: Stephen K. Tyring, MD, PhD, Department of Dermatology, University of Texas Medical Branch, Galveston, TX 77555-1070. E-mail: tyring@flash.net.

Copyright © 1999 by the American Academy of Dermatology, Inc. 0190-9622/99/\$8.00 + 0 16/2/98761

years, and 10.1/1000 in those older than 80 years of age.¹⁴ Overall, each person who has a history of varicella experiences an approximately 20% chance of acquiring shingles in his/her lifetime. The incidence of both of these manifestations of VZV infection is likely to change since the Food and Drug Administration's (FDA) approval of live attenuated (OKA) varicella vaccine. There is no evidence that herpes zoster can be directly acquired through contact with patients with either varicella or zoster.¹⁴⁻¹⁶

PATHOGENESIS

Primary varicella

Acquired by inhalation of respiratory secretions or contact with skin lesions, primary varicella initially infects the conjunctiva or the mucosa in the upper respiratory tract. This is followed by the first cycle of viral replication, which takes place in the regional lymph nodes on days 2 through 4, and a primary viremia, which occurs between days 4 and 6. Next, a second replication cycle follows, which occurs in the liver, spleen, and other organs. Finally, a secondary viremia occurs, which seeds the body with viral particles that invade first the capillary endothelial cells, then the capillaries, and ultimately the epidermis on approximately days 14 to 16.¹⁷

Herpes zoster

Although not fully understood, it is believed that during the course of primary varicella VZV spreads from the skin and mucosal lesions into the sensory nerve endings. From there, it travels centripetally along these nerve fibers until it reaches the dorsal ganglion cells where it enters a latent state. Then, by mechanisms not completely understood, it is reactivated, probably as a result of a decline in VZV-specific cell-mediated immunity (CMI), specifically a decreased T-cell proliferation in response to VZV antigen.¹⁸ One particularly interesting study showed the incidence of zoster to be less in pediatricians with presumably greater contact to varicella (and thus increased CMI to VZV) than in psychiatrists or dermatologists.¹⁹ This decline in CMI is seen among persons with increased incidence of herpes zoster, including the elderly and persons with HIV infection or other immunocompromising conditions such as organ transplants (with immunosuppression), malignancy necessitating chemotherapy or radiotherapy,²⁰ or long-term corticosteroid use.²¹ Among cancer patients, the highest risk of acquiring herpes zoster is associated with patients with leukemia or lymphoma; in fact, approximately 20% to 50% of patients with Hodgkin's disease develop herpes zoster,²²⁻²⁹ and it is usually shortly after the initiation of either chemotherapy (1 month) or radiotherapy

(7 months).³⁰ Similarly, 20% to 40% of bone marrow transplant recipients will develop herpes zoster in the first year after their transplants.³¹⁻³⁴ Among patients with HIV infection, herpes zoster can be the first sign of infection,^{35,36} and the lesions may have an unusual appearance and may recur several times.³⁷⁻⁴³ Contrary to what was previously believed, shingles is not a reliable initial indication of an underlying subclinical malignancy because a study of 590 patients with zoster had no higher incidence of cancer than that of the general population.⁴⁴ After reactivation, VZV undergoes an initial phase of replication within the affected sensory ganglion and produces active ganglionitis. The inflammatory response and neuronal necrosis that result cause severe neuralgia. This pain intensifies as the virus travels down the sensory nerve, producing radiculoneuritis.

CLINICAL MANIFESTATIONS

Primary varicella

Although occasionally preceded by a prodrome of symptoms such as headache, myalgia, nausea, anorexia, and vomiting in older children and adults,⁴⁵ in young children the illness usually begins abruptly with the simultaneous onset of rash, low-grade fever, and malaise. Small red macules appear on the face and trunk and progress rapidly over 12 to 14 hours to papules, vesicles, pustules, and finally crusts. These lesions are usually most abundant centrally and on the proximal upper extremities, with relative sparing of the distal or lower extremities. Almost universal is the symptom of pruritus associated with the skin lesions. Perhaps most characteristic is the simultaneous presence of lesions in all stages of development. The characteristic vesicle has been likened to "a dewdrop on a rose petal."

Although usually a mild self-limited illness in immunocompetent children, varicella can occasionally result in significant morbidity, with 4500 otherwise healthy children per year hospitalized with primary varicella. However, varicella infection in adults is usually more severe, with more skin lesions present and more prominent and prolonged fever and constitutional symptoms.

Multiple complications can result from primary varicella infection; the most common is bacterial superinfection, with subsequent scarring. This can manifest as impetigo, furuncles, cellulitis, erysipelas, or bullous skin lesions from the elaboration of staphylococcal exfoliative toxin.⁴⁶ The most common extracutaneous complication of VZV infection is central nervous system (CNS) involvement. This includes Reye's syndrome, acute cerebral ataxia, encephalitis, meningoencephalitis, polyradiculitis,

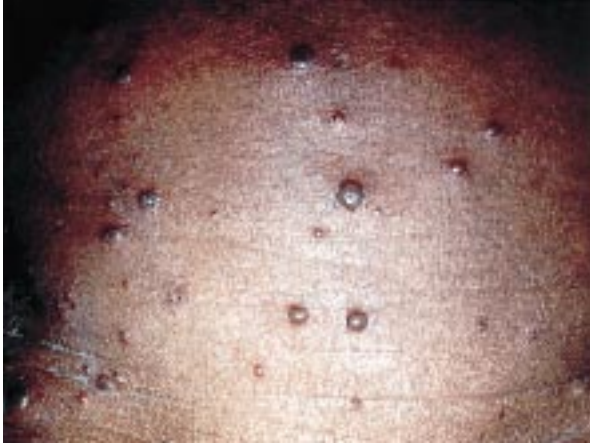


Fig 1. Primary varicella (chickenpox) in an 80-year-old man.

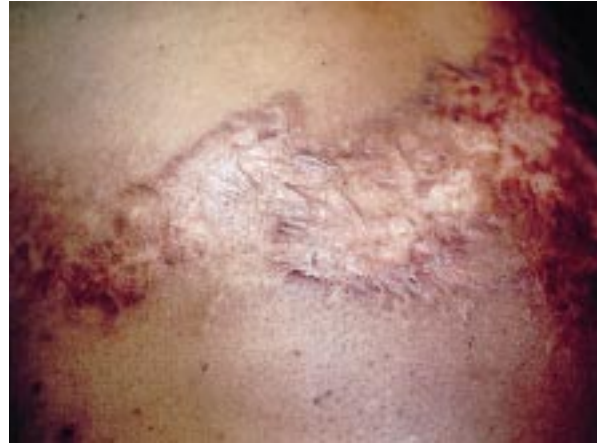

Fig 2. Hypertrophic scar from herpes zoster in an HIV-seropositive man.

and myelitis (eg, Guillain-Barre syndrome).⁴⁷ In adult varicella (Fig 1), varicella pneumonia is a frequent complication, occurring in 1/400 cases.⁴⁸ The mortality rate of adult varicella pneumonia is high, with death occurring in 10% of immunocompetent and 30% of immunocompromised patients.⁴⁹ Rarely, myocarditis, glomerulonephritis, appendicitis, pancreatitis, hepatitis, Henoch-Schönlein vasculitis, orchitis, arthritis, optic neuritis, keratitis, or iritis can result.⁴⁵

In pregnancy, maternal varicella infection can cause a wide spectrum of congenital disease from asymptomatic latency to severe congenital defects or even fetal wastage.⁵⁰ Fetal developmental complications are most common when maternal infection occurs in the first trimester and include hypoplastic limbs, cicatricial skin lesions, cortical atrophy, ocular abnormalities, psychomotor retardation, and low birth weight. After the first 20 weeks of pregnancy, the risk of congenital malformation changes to approximately 2%.

In immunocompromised children or adults, varicella can be associated with significant morbidity and mortality. They can experience a persistent viremia, a prolonged febrile period, a more extensive rash (often with hemorrhagic and/or purpuric lesions) and are more likely to have involvement of the lungs, liver, or CNS.⁵¹

Herpes zoster

Intense pain in the involved dermatome precedes the rash of herpes zoster in more than 90% of cases. This pain typically occurs approximately 1 to 3 days before the onset of the rash, but may precede it by a week or more. This pain is subject to a wide array of misdiagnoses, including myocardial infarction,

pleurisy, cholecystitis, appendicitis, duodenal ulcer, ovarian cyst, herniated intervertebral disc, thrombophlebitis, or even biliary or renal colic. In approximately 5% of patients (usually children), this pain is compounded by other prodromal symptoms of fever, malaise, and headache. Occasionally, a patient with this dermatomal pain and serologic or virologic evidence of zoster has failed to develop the rash associated with zoster, a condition known as zoster sine herpette (zoster without rash).⁵²

Once the characteristic unilateral dermatomal rash appears, the diagnosis is almost certain. This rash begins as erythematous macules and papules, which progress first to vesicles (within 12-24 hours), then the pustules (in 3-4 days), and finally to crusts (in 7-10 days). Scarring can result, particularly in dark-skinned persons (Fig 2). In addition, regional lymphadenopathy is usually present. Generally, the rash is located at the site which was most severely affected by primary varicella.¹⁴ Therefore the most common places of involvement are the facial (V-1) and midthoracic to upper lumbar dermatomes (T3-L2) (Fig 3), although any dermatome can be affected (Fig 4).

Similar to chickenpox, the pain and rash of zoster are usually more severe in immunocompromised and elderly patients.⁵¹ In contrast, when zoster occurs in immunocompetent children (Fig 5) or young adults, the rash tends to evolve more rapidly and the neuralgia usually resolves as the crusts fall off.

Probably the most feared and debilitating complication of zoster is postherpetic neuralgia (PHN). Although various definitions have been used, this clinical entity exists when pain persists either after a certain time period or after all crusts have fallen off. Unfortunately, PHN is extremely common, affecting

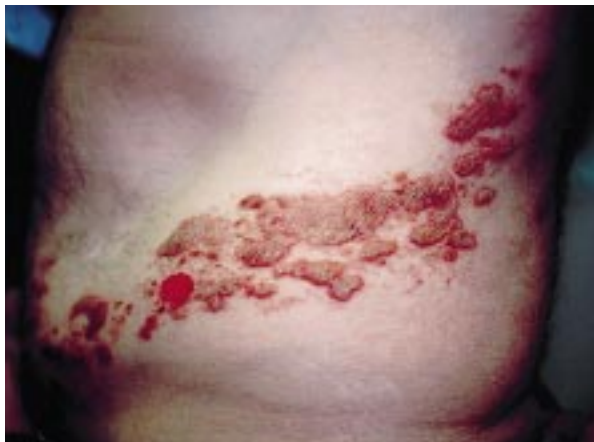

Fig 3. Herpes zoster in the L-1 dermatome.

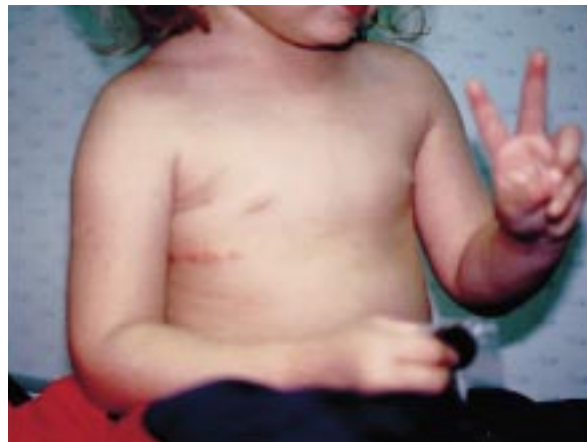

Fig 5. Herpes zoster in a 2-year-old girl.

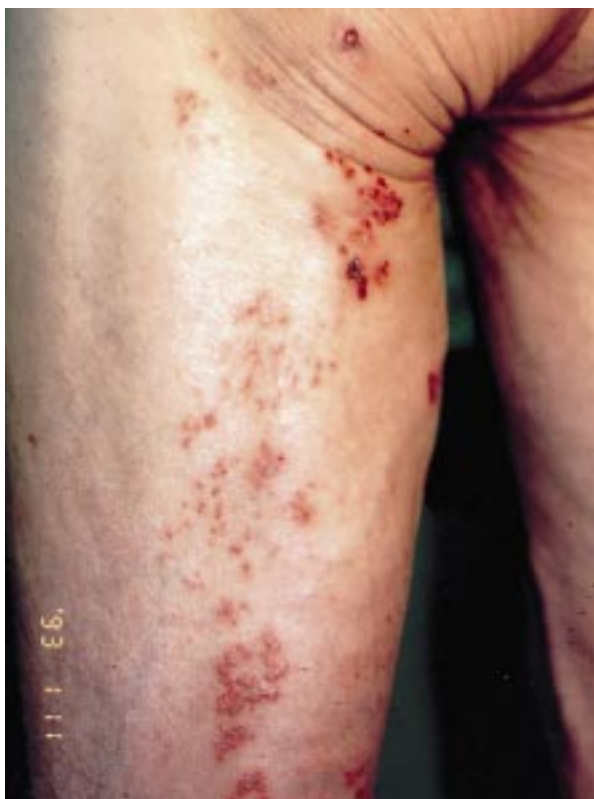

Fig 4. Herpes zoster in distribution of sacral nerves 1 and 2.

10% to 15% of all patients with zoster⁵³ and at least 50% of patients older than 60 years of age. Usually, patients experience a significant reduction of pain within 6 months, although this is variable.⁵⁴ Other abnormal sensations can persist after healing of skin lesions and include pruritus, paresthesia, dysesthesia, or anesthesia.

A particularly high complication rate is seen with ophthalmic zoster. Affecting 7% of all cases of zoster,⁴⁹ ophthalmic zoster is complicated by ocular disease in 20% to 70% of patients.⁵³ Associated cicatricial lid retraction, paralytic ptosis, (acute epithelial) keratitis, scleritis, uveitis, secondary glaucoma, oculomotor palsies, chorioretinitis, optic neuritis, or panophthalmitis are seen, all with potential for visual impairment or even blindness. Of particular concern is involvement of the nasociliary division of the ophthalmic nerve. This can be recognized by vesicles present on the side and the top of the nose, also known as Hutchinson's sign (Fig 6).⁵⁵

Other nervous system complications are seen occasionally with zoster. The Ramsay Hunt syndrome is caused by involvement of the facial or auditory nerves and consists of ipsilateral facial palsy in combination with lesions of the external ear, tympanic membrane, or anterior two thirds of the tongue. It can result in tinnitus, vertigo, deafness, otalgia, or loss of taste. In addition, meningoencephalitis and myelitis have been reported in 0.2% to 0.5% of patients and are associated with headache, fever, photophobia, meningeal irritation, vomiting, nerve palsies, or altered mentation.^{47,56-60} Rarely, zoster involvement of the vagus nerve or its ganglia can result in dysphagia, nausea, vomiting, gastric upset, or cardiac irregularities. Motor paralysis from direct extension from the sensory ganglion to anterior horn cells occurs in 1% to 5% of patients with zoster.⁶¹⁻⁶⁴ This paralysis usually occurs in the first 2 to 3 weeks after rash onset and can persist for several weeks. Localized motor deficiencies are found in up to 20% of patients with zoster involving the facial nerve or the nerves of the extremities.⁴⁷ A delayed CNS complication of ophthalmic zoster is granulomatous cerebral angiitis with symptoms often occur-

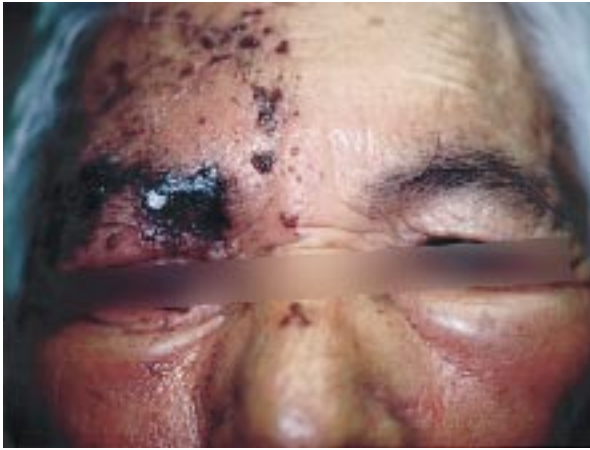

Fig 6. Herpes zoster in first branch of trigeminal nerve (ie, ophthalmic zoster) with lesions on bridge of the nose (ie, Hutchinson's sign) as well as contralateral eyelid edema.

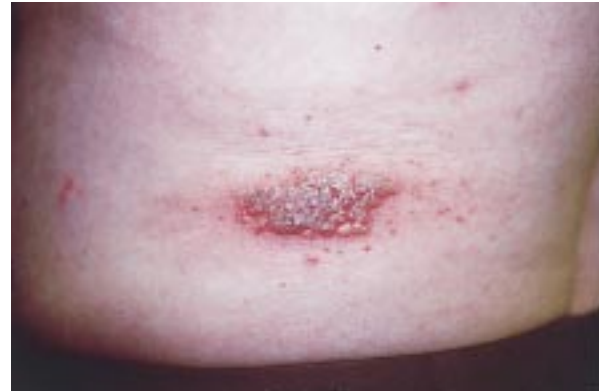


Fig 7. Primary dermatome (ie, thoracic) affected by herpes zoster in a patient receiving radiation therapy for carcinoma of the larynx.

ring weeks to months after the attack. This has been associated with a rather high mortality rate (15%) and may present as transient ischemic attacks, stroke-in-evolution, or isolated or multiple cerebral infarctions. However, the most frequent CNS finding is asymptomatic cerebrospinal fluid abnormalities such as a lymphocytotic pleocytosis and elevated protein.

Although uncommon in immunocompetent patients, zoster has a high risk of dissemination (up to 40%)⁴⁹ in immunocompromised persons (Figs 7 and 8). Defined as more than 20 vesicles outside the primary and immediately adjacent dermatomes, cutaneous dissemination is followed by visceral (lungs, liver, brain) involvement in 10% of these high-risk patients. Occasionally, a few vesicles can be found remote from the primarily affected dermatome in immunocompetent patients (17%-35%),⁶⁵ which probably results from hematogenous spread of the virus. In addition, HIV patients with zoster showed increased neurologic (eg, aseptic meningitis, radiculitis, and myelitis)⁶⁶ and ophthalmologic complications, particularly peripheral outer retinal necrosis.⁶⁶⁻⁶⁸

DERMATOPATHOLOGY

The initial test of choice is usually a Tzanck smear performed by scraping the base of an early lesion and then staining with hematoxylin-and-eosin, Giemsa, Wright's, toluidine blue, or Papanicolaou. With herpes simplex or herpes zoster infections, multinucleated giant cells and epithelial cells containing acidophilic intranuclear inclusions can be seen. However, VZV cannot be differentiated from HSV infection using a Tzanck smear.

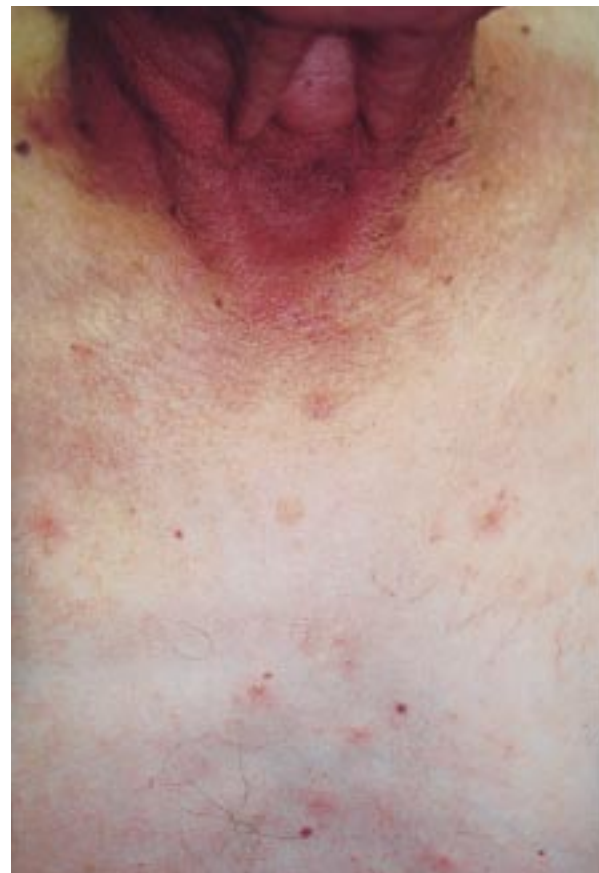

Fig 8. Disseminated vesicles of herpes zoster in patient seen in Fig 7.

LABORATORY FINDINGS

Multiple tests can be used to differentiate VZV from HSV including culture, serology, direct immunofluorescence, and molecular techniques. Culture, although specific, is not always easily

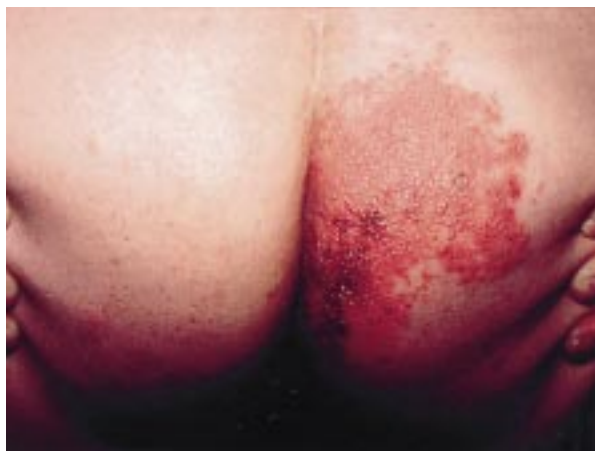

Fig 9. Perianal herpes zoster in an HIV-seropositive man.

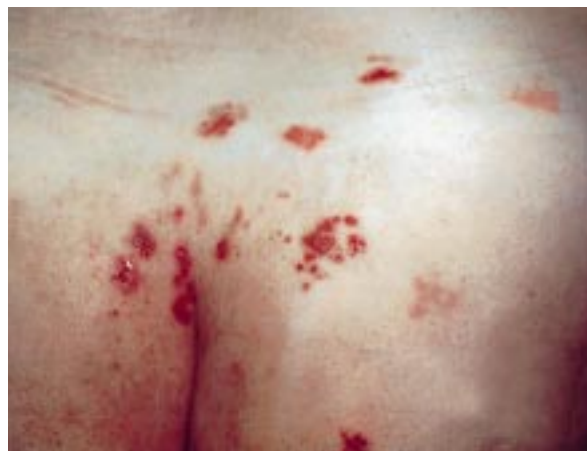

Fig 10. Zosteriform herpes simplex virus type 2.

obtained because VZV is a labile virus that is cultured much less readily than HSV.⁶⁹⁻⁷¹ Although limited by cross-reactivity with HSV, serologic tests such as complement fixation can be used to retrospectively diagnose VZV infection.⁷² Currently, the most useful test to diagnose VZV infection is direct immunofluorescence of cellular material from skin lesions. However, molecular techniques with high sensitivity such as dot-blot hybridization and polymerase chain reaction have been used recently to detect VZV in the skin lesions, peripheral blood mononuclear cells, and other tissues of patients with VZV infection, and may be the diagnostic tests of choice in the future.^{70,73,74}

DIFFERENTIAL DIAGNOSIS

The varicella rash associated with chickenpox can sometimes be confused with other viral exanths, insect bites, scabies, erythema multiforme, papular urticaria, drug eruptions, or other vesicular dermatoses such as dermatitis herpetiformis. In contrast, zoster is primarily confused with dermatomal HSV infections, particularly anogenital herpes (Figs 9 and 10). However, "shingles" that recurs in the sacral area is almost always herpes simplex virus 2. Other conditions occasionally confused with zoster include contact dermatitis, burns, arthropod reactions, localized bacterial or viral skin infections, or even vaccinia autoinoculation.

DIAGNOSIS

Usually diagnosed clinically, varicella is often diagnosed easily when there is the characteristic rash in combination with a history of exposure within the preceding 2 to 3 weeks.^{61,75,76} As mentioned previously, while the diagnosis of zoster is also usually made clinically, viral cultures, direct fluorescent anti-

bodies, or Tzanck smears may be performed to confirm the clinical impression.

TREATMENT/PROPHYLAXIS OF CHICKENPOX

In the past, otherwise healthy children with primary varicella have been treated only symptomatically with calamine lotion, tepid baths, cool compresses, and antipyretics (excluding aspirin secondary to its association with Reye's syndrome).^{77,78} Although acyclovir (20 mg/kg 4 times a day for 5 days) was shown to decrease both the duration and severity of chickenpox,⁷⁹ this has not received widespread acceptance because of the high cost of treatment, difficulty in rapid institution of therapy, and concern of development of acyclovir-resistant strains of VZV. In addition, the usually benign course of the disease and low rate of complications in this population weakens the motivation to start antiviral therapy. By allowing the child to return to school 1 to 2 days earlier, however, antiviral therapy may be considered cost-effective if it allows the parent(s) or guardian(s) to return to work earlier.

In contrast, acyclovir is much more commonly used to treat primary varicella in immunocompromised patients.^{80,81} Although vidarabine and parenteral human interferon alfa have also been proven to be efficacious in the treatment of varicella in this population,⁸²⁻⁸⁶ the presence of significant toxicities (neurotoxicity with vidarabine and fever and myalgias with interferon alfa) have limited their use. Therefore acyclovir (intravenous dosing of 500 mg/m² every 8 hours for 7-10 days)⁸⁷ continues to be the drug of choice for treatment of varicella in immunocompromised patients.

Naturally, the prevention of varicella would be preferable to treatment of an existing infection. Varicella-zoster immune globulin (VZIG) has been

used in the past to treat immunocompromised patients who have received significant exposure to varicella (recommended dose is 125 U/10 kg). Unfortunately, one third to one half of these patients still develop clinical infection.⁸⁸ Therefore the recently approved live attenuated VZV vaccine (OKA strain) has been received with much interest. This vaccine appears to be both highly efficacious (96% seroconversion in healthy children in one study)⁸⁹ and very safe, with only such mild side effects as slight varicelliform rash, fever, and infection-site reactions reported.^{90,91} In addition, the incidence of zoster occurring after vaccination seems to be decreased compared with that after natural infection.⁹² A recent study⁹³ found that varicella occurred in 14% of vaccinated children in a child care center versus 88% of unvaccinated children. In addition, the vaccinated children had less severe disease and fewer days of absence from school than the unvaccinated children. Finally, the large societal savings in time off from work to care for sick children and the high cost of caring for varicella-related complications make the vaccine appear to be cost-effective. In fact, one study estimated that an effective varicella vaccination program would be expected to have a net savings of \$384 million per year in the United States in discounted costs from the social perspective.⁹⁴

TREATMENT OF ZOSTER (ACUTE INFECTION)

Although no antiviral treatment has been shown to totally prevent PHN, early therapy has been found to reduce its duration. Currently, acyclovir, idoxuridine, famciclovir, vidarabine, foscarnet, valacyclovir, and interferon alfa have all been shown to be efficacious in treating VZV infections. Idoxuridine was the first antiviral agent to be evaluated for the treatment of zoster.⁹⁵ It is an antimetabolite of thymidine and acts to inhibit DNA synthesis after being intracellularly phosphorylated to idoxuridine triphosphate. However, because viral and host cell DNA are equally affected, it is too toxic for systemic use but instead was used topically in a dimethylsulfoxide base. A 40% solution applied every 4 to 6 hours had beneficial effects on rash healing, acute pain, and the prevention of PHN.⁹⁵ However, other studies^{96,97} showed no effect on PHN. Therefore, because of the lack of effect on PHN in combination with a high potential for toxicity, idoxuridine is no longer used routinely in the treatment of acute zoster.

Vidarabine was the first systemic antiviral agent to be approved by the FDA. It acts as an analogue of the nucleoside adenosine and interferes with DNA synthesis. When vidarabine was given intravenously to immunocompromised patients (10 mg/kg every

12 hours for 5 days), viral shedding, time to cessation of pain and new vesicle formation, total healing time, cutaneous dissemination, visceral complications, and the duration of PHN were all reduced.^{51,98} However, later studies comparing vidarabine with acyclovir found that the rates of cutaneous healing, resolution of acute pain, and incidence of PHN did not differ between the two agents in the treatment of patients with disseminated zoster.⁹⁹ In addition, the difficulty of administration and significant side effects of vidarabine (neurotoxicity, myelosuppression) have made acyclovir much more commonly used.

Acyclovir has (until recently) been the drug of choice in the treatment of herpes zoster. An analogue of the nucleoside guanosine, it is phosphorylated (first by viral thymidine kinase, then by cellular kinases) into acyclovir triphosphate. It then inhibits viral DNA polymerase by acting as a competitive inhibitor of guanosine triphosphate.¹⁰⁰ Available in topical, intravenous, and oral formulations, only the intravenous and oral forms have any role in the treatment of VZV. When given to immunocompetent and immunocompromised patients, intravenous acyclovir (500 mg/m²/day for 5-7 days) was found to reduce acute pain and speed cutaneous healing.¹⁰¹⁻¹⁰⁴ The oral form is limited by a poor availability (15%-20%). However, when it was given at a dose of 800 mg 5 times daily (currently recommended regimen: 7 days) accelerated rash healing was seen and pain was reduced.¹⁰⁵⁻¹¹⁰ However, several trials have shown no benefit in the use of acyclovir in reducing the duration of PHN.¹⁰¹⁻¹⁰³ Adverse effects seen with acyclovir are rare but include headaches, nausea, diarrhea, and renal toxicity (in renal patients who thus should have their doses reduced). Rarely, CNS toxicity can occur with symptoms of disorientation, delirium, seizures, tremor, or slurred speech.¹¹¹

Valacyclovir is a prodrug of acyclovir (the L-valyl ester of acyclovir) with the advantage of greatly increased oral bioavailability (65%).^{112,113} It was approved by the FDA for the treatment of shingles in June 1995. In one trial comparing valacyclovir 1 g 3 times daily (currently recommended course: 7 days) to acyclovir 800 mg 5 times daily, valacyclovir was found to be as effective in decreasing the appearance of new lesions, time to crusting, and time to 50% healing.¹¹⁴ In addition, valacyclovir reduced the median duration of pain from 60 days after healing (with acyclovir) to 40 days. Six months after healing, only 19% of patients taking valacyclovir had pain compared with 26% of patients taking acyclovir.¹¹⁵ Finally, valacyclovir appears to have a similar safety profile to acyclovir, with some nausea, vomiting,

diarrhea, abdominal pain and headache reported,¹¹⁶ which may have been due to VZV and/or to pain medications. However, no nephropathy or neurotoxicity has been seen.

Famciclovir was approved by the FDA for the treatment of herpes zoster in June 1994 (500 mg 3 times/day for 7 days). The active metabolite of famciclovir is penciclovir, which is a guanosine analogue. Like acyclovir, penciclovir undergoes 3 phosphorylations (first by viral thymidine kinase, then by cellular enzymes) to penciclovir triphosphate, which acts by inhibiting viral DNA polymerase and thus blocks viral DNA synthesis and replication.¹¹⁷ Like valacyclovir, it offers the advantage of increased bioavailability (77%) over acyclovir.¹¹⁸ In a trial comparing famciclovir with acyclovir, famciclovir was found to be equal to acyclovir in promoting cutaneous healing and reducing the duration of acute pain.¹¹⁹ In addition, it was found to decrease the duration of PHN among elderly patients¹²⁰ when compared with placebo. Finally, a recent large multicenter study found famciclovir and acyclovir to have equivalent clinical efficacies in the treatment of ophthalmic herpes zoster.¹²¹ Like valacyclovir, it offers the more convenient dosing of 3 times daily. Studies comparing famciclovir with valacyclovir for the treatment of herpes zoster are currently under way.

Sorivudine is another nucleoside analogue that was investigated for the treatment of VZV infections. In vitro, it exhibits 1000-fold more activity against VZV than acyclovir.¹²² Unlike the other nucleoside analogues mentioned previously, it requires viral thymidine kinase for both its first and second phosphorylations. One trial comparing sorivudine (40 mg/day for 7 days) with acyclovir in HIV-positive patients with shingles showed sorivudine to be more effective in promoting the cessation of new vesicle formation.¹²³ However, another study in HIV-infected patients showed no difference between sorivudine (40 mg/day for 10 days) and acyclovir (800 mg five times daily) in time to resolution of zoster-associated pain, the frequency of dissemination, or the frequency of zoster recurrence. However, there was a trend favoring sorivudine for cessation of new vesicle formation, and the time to total lesion crusting was diminished.¹²⁴ Major toxicity (myelosuppression) occurs if sorivudine is administered concurrently with 5-fluorouracil. A metabolite of sorivudine inhibits an enzyme (dihydropyrimidine dehydrogenase) that is required in the metabolism of 5-fluorouracil, causing toxic levels to accumulate.¹²⁵

Other drugs that have been used with varying efficacies against VZV infection include netivudine, interferon alfa, foscarnet, and corticosteroids. Netivudine was another nucleoside analogue that

was found to have excellent in vitro activity against VZV.¹²⁶ However, in a multicenter, double-blind study of immunocompetent patients older than 50 years of age, acyclovir led to faster cessation of all pain, with similar rash outcomes and adverse event profiles to netivudine.¹²⁷ Interferon alfa, although somewhat efficacious,⁸³ is associated with such side effects as fever, myalgias, lethargy, and headaches.¹²⁸ Corticosteroids have long been used in the treatment of herpes zoster by many practitioners. Hoping to decrease inflammation, and thereby decrease further nerve damage and the chronic pain associated with it, they have been used both alone and in combination with antiviral drugs. Although some studies demonstrated a reduction in persistent pain¹²⁹ or accelerated healing¹³⁰ in patients treated with corticosteroids, a study by Wood et al³¹ showed no long-term benefit when corticosteroids were added to the acyclovir regimen. While a decrease of acute pain and a quicker rash resolution was seen, there was no effect on PHN, and the incidence of adverse effects were higher in the groups treated with corticosteroids. In addition, a recent study by Whitley et al¹³² found no difference in pain at 6 months when acyclovir and prednisone were used together compared with acyclovir alone, prednisone alone, or double placebo (acyclovir and prednisone). The new antivirals, valacyclovir and famciclovir, are possibly more effective and certainly more convenient than the complicated dosing regimen required by acyclovir plus prednisone. In contrast, foscarnet is effective against acyclovir-resistant herpes strains in patients with AIDS.¹³³ It is an organic analogue of inorganic pyrophosphate that prevents viral replication by reversibly inhibiting viral DNA polymerase.¹³⁴ Unlike most of the nucleoside analogues, it is not dependent on the presence of thymidine kinase and is active without any activation or phosphorylation. Therefore it is active against thymidine kinase-negative strains, an increasing problem in HIV-positive persons.

Finally, new drugs with VZV activity are currently under investigation. ABT-606 is an acyclic guanosine analogue that acts by inhibiting viral DNA polymerase and has demonstrated potent activity against VZV in vitro. In addition, lobucavir is another guanosine nucleoside analogue with in vitro activity against VZV. Clinical studies are pending.¹³⁵

TREATMENT OF PHN

No single treatment of PHN is consistently effective, but the duration and severity of PHN can be effectively reduced by treating acute herpes zoster with the appropriate dosage of acyclovir, valacy-

clovir, or famciclovir. Almost all published studies have defined immediate treatment as that which begins within 72 hours of the first vesicle. Because patients frequently present after 72 hours of vesicles, the question often arises as to the effectiveness of initiating therapy after this time. Although the answer to this question is unclear, it appears reasonable to use antiviral therapy in the patient presenting after 72 hours of the appearance of vesicles if the lesions are not completely crusted and she/he is older than 50 years of age, immunocompromised, and/or has trigeminal zoster. Although no antiviral agent has demonstrated any efficacy in the treatment of PHN, a variety of modalities including analgesics, narcotics, cutaneous stimulation, tricyclic antidepressants, capsaicin, biofeedback, and nerve blocks have been reported to be effective in relieving pain in some patients. Narcotics and analgesics are not generally effective in the treatment of PHN, and the potential for dependency with long-term use discourages the use of narcotics. Anticonvulsants such as carbamazepine have been found to have efficacy in painful conditions such as trigeminal neuralgia in which lancinating pain is a prominent part of their condition.^{136,137} However, since this type of pain is not a common feature of PHN, little benefit has been shown with their use.^{138,139} In addition, one half of the patients treated by Killian and Fromm¹³⁸ experienced significant side effects with their use. In contrast, gabapentin, a structural analogue of gamma-aminobutyric acid which is marketed as an anticonvulsant, was recently demonstrated to be effective in the treatment of PHN.¹⁴⁰ Gabapentin was statistically significantly better than placebo in reducing the average daily pain score and demonstrated benefits in restoring normal sleep patterns. Although adverse events were more common in the gabapentin recipients, withdrawals from the study were comparable with the placebo group.

Antipsychotics such as chlorprothixene, fluphenazine, and haloperidol have also been tried (often in combination with antidepressants) but when used alone in a placebo-controlled trial, chlorprothixene was found to be of marginal efficacy.¹⁴¹ Local treatments such as the local injection of bupivacaine, cryoanalgesia, and sympathetic blockade have been reported to provide relief in some patients.¹⁴²⁻¹⁴⁵ In addition, such topical treatments as topical lidocaine, eutectic mixture of local anesthetics (EMLA) cream, or transcutaneous electrical stimulation have been used with some success.¹⁴⁶⁻¹⁴⁹ One topical treatment that has had significant success is capsaicin, which acts by enhancing the release or inhibiting the reaccumulation of substance P from cell bodies and nerve terminals. In one study by

Bernstein et al,¹⁵⁰ almost 80% of the patients treated experienced some pain relief. Some patients are unable to tolerate the burning associated with capsaicin, but some authors have advocated applying EMLA or topical lignocaine before its use.¹⁵¹ Patients should be cautioned not to apply capsaicin to the unhealed skin lesions of acute zoster. Surgical measures have been mostly disappointing,^{152,153} although some success was initially found by Friedman and Hashold¹⁵⁴ with the use of the dorsal root entry zone lesion procedure. This neurodestructive technique involves making radiofrequency lesions at multiple levels of the sensory nerve root entry zones that are involved in the pain, but it is no longer recommended for the treatment of PHN. Of greatest efficacy, perhaps, is the use of tricyclic antidepressants. They are thought to act in a manner independent of their antidepressant actions (since relief of PHN occurs at less than antidepressant dosages). In fact, some authors¹⁵⁵ recommend starting amitriptyline at low doses (10-25 mg) and gradually increasing this to doses of 50 to 75 mg over 2 to 3 weeks in all patients older than 60 years of age as soon as shingles is diagnosed. They report this regimen to decrease the incidence of PHN by 50%. Amitriptyline, maprotiline, and desipramine have all been shown to be effective,¹⁵⁶⁻¹⁵⁸ but desipramine might be preferable because of its low anticholinergic and sedative effects. These drugs probably act by blockade of norepinephrine reuptake. In contrast, serotonin reuptake inhibitors such as zimelidine have not been shown to be effective.¹⁵⁹

PROPHYLAXIS OF HERPES ZOSTER

A live attenuated vaccine (OKA varicella vaccine) against VZV received FDA approval in March 1995. This vaccine was shown to be 100% efficacious in preventing varicella in one clinical trial.¹⁶⁰ In addition, among children with leukemia who received the vaccine, the incidence of zoster was decreased compared with children with leukemia who had experienced natural varicella infections.¹⁶¹ However, while it was initially hoped zoster would not occur in vaccinated patients at all, some patients have had herpes zoster caused by vaccine-type virus.¹⁶² Finally, it is believed that the vaccine will be cost-effective in terms of medical and work-loss costs.⁹⁴ Studies are now under way to see whether the immunization of healthy adults with OKA vaccine will prevent shingles. In one study of adults older than 50 years of age with a history of primary zoster, an increase of VZV-specific T lymphocytes and VZV immunity was seen.¹⁶³ However, in another study of adults older than 55 years of age, anti-VZV antibody levels were enhanced for only 1 year after immu-

nization, although VZV-responding T cells remained elevated. In addition, immunity failed to increase in 10% to 15% of vaccinees regardless of dose.¹⁶⁴ In contrast, another study showed cell-mediated immunity was still detected at 5 years after immunization in 87% of children and 94% of adults.¹⁶⁵ Acyclovir has been tried in suppressive doses to try and prevent zoster in groups at high risk because of immunocompromise. Although some benefit has been found when used in the peritransplant period of bone marrow transplant recipients,¹⁶⁶ long-term use in HIV-positive patients has been associated with the development of acyclovir-resistant strains of VZV.^{37,39,42,167,168}

CONCLUSION

Infection with VZV is unique because of its two clinical manifestations. Although the increasing use of OKA vaccine may decrease the incidences of both primary varicella and zoster for the next several decades, we will continue to see zoster as a consequence of previous varicella infection. Therefore the need for the development and evaluation of new antivirals, as well as more effective treatment of PHN will continue. In addition, the rise in incidence of HIV infection will also continue to make safe and effective treatments of immunocompromised hosts with chickenpox and zoster infections necessary, particularly as rates of acyclovir-resistant VZV strains increase.

We extend special thanks to Mrs Michelle Harden and Miss Amy Shaabani for their help in preparing this manuscript.

REFERENCES

- Roizman B, Carmichael LE, Deinhardt F, de-The G, Nahmias AJ, Plowright W, et al. Herpes viridae: definition, provisional nomenclature and taxonomy. *Intervirology* 1981;16:201-17.
- Gordon JE. Chickenpox: an epidemiological review. *Am J Med Sci* 1962;244:362-89.
- Scott-Wilson JH. Why "chicken" pox? *Lancet* 1978;1:1152.
- Grose C, Ng TI. Intracellular synthesis of varicella-zoster virus. *J Infect Dis* 1992;166(suppl 1):S7-S12.
- Von Bokay J. Über den etiologischen Zusammenhang der Varizellen mit gewissen Fällen von Herpes Zoster Wien *Zlin Wochenschr* 1909;22:1323-6.
- Bruusgaard E. The mutual relation between zoster and varicella. *Br J Dermatol Syphilol* 1932;44:1.
- Weller TH, Stoddard MB. Intracellular inclusion bodies in cultures in human tissue inoculated with varicella vesicle fluid. *J Immunol* 1952;68:311.
- Gershon AA, Raker R, Steinberg S, Topf-Olstein B, Drusin LM. Antibody to varicella-zoster virus in parturient women and their offspring during the first year of life. *Pediatrics* 1976;58:692-6.
- Wallace MR, Hooper DG, Pyne JM, Graves SJ, Malone JL. Varicella immunity and clinical disease in HIV-infected adults. *South Med J* 1994;87:74-6.
- Wharton M. The epidemiology of varicella-zoster virus infections. *Infect Dis Clin North Am* 1996;10:571-81.
- Strueiving JP, Hyams KC, Tuellar JE, Gray GC. The risk of measles, mumps, and varicella among young adults: a serosurvey of US Navy and Marine Corps recruits. *Am J Public Health* 1993;83:1717-20.
- McGregor JA, Mark S, Crawford GP, Levin MJ. Varicella zoster antibody testing in the care of pregnant women exposed to varicella. *Am J Obstet Gynecol* 1987;157:281-4.
- Junker AK, Angus E, Thomas EE. Recurrent varicella-zoster infections in apparently immunocompetent children. *Pediatr Infect Dis J* 1991;10:569-75.
- Hope-Simpson RE. The nature of herpes zoster: a long-term study and a new hypothesis. *Proc R Soc Lond B* 1965;58:9-20.
- Seiler HE. A study of herpes zoster particularly in its relationship to chickenpox. *J Hyg (Camb)* 1949;47:253.
- Straus SE. Shingles: sorrows, salves, and solutions. *JAMA* 1993;269:1836-9.
- Grose C. Variation on a theme by Fenner: the pathogenesis of chickenpox. *Pediatrics* 1981;68:735-7.
- Arvin AM. Cell-mediated immunity to varicella-zoster virus. *J Infect Dis* 1992;166(suppl 1):S35-S41.
- Solomon BA, Kaporis AG, Glass AT, Simon SI, Baldwin HE. Lasting immunity to varicella in doctors study (L.I.V.I.D. study). *J Am Acad Dermatol* 1998;38:763-5.
- Ruckdeschel JC, Schimpff SC, Smyth AC, Mardiney MR Jr. Herpes zoster and impaired cell-associated immunity to the varicella zoster virus in patients with Hodgkin's disease. *Am J Med* 1977;62:77-85.
- Arvin AM. Immune responses to varicella-zoster virus. *Infect Dis Clin North Am* 1996;10:529-70.
- Dolin R, Reichman RC, Mazur MH, Whitley RJ. Herpes zoster-varicella infection in immunosuppressed patients. *Ann Intern Med* 1978;89:375-88.
- Juel-Hensen BE, MacCallum FO. Herpes simplex, varicella and zoster. Philadelphia: JB Lippincott; 1972; p. 72-7.
- Sokal JE, Firat D. Varicella-zoster infection in Hodgkin's disease. *Am J Med* 1965;39:452-63.
- Schimpff S, Serpick A, Stoler B, Rumack B, Mellin H, Joseph JM, et al. Varicella-zoster infection in patients with cancer. *Ann Intern Med* 1972;76:241-54.
- Feldman S, Hughes WT, Kim HY. Herpes zoster in children with cancer. *Am J Dis Child* 1973;126:178-84.
- Goffinet DR, Glatstein EJ, Merigan TC. Herpes zoster-varicella and lymphoma. *Ann Intern Med* 1972;76:235-40.
- Goodman R, Jaffe N, Filler R. Herpes zoster in children with stage I-III Hodgkin's disease. *Radiology* 1976;118:429-31.
- Reboul F, Donaldson SS, Kaplan HS. Herpes zoster and varicella infections in children with Hodgkin's disease: an analysis of contributing factors. *Cancer* 1978;41:95-9.
- Rusthoven JJ, Ahlgren P, Elhakim T, Pinfold P, Reid J, Stewart L, et al. Varicella-zoster infection in adult cancer patients: a population study. *Arch Intern Med* 1988;148:1561-6.
- Arvin AM. Cell-mediated immunity to varicella zoster virus. *J Infect Dis* 1992;166:S35-S41.
- Ljungman P, Lonngqvist B, Gahrton G, Ringden O, Sundqvist VA, Wahren B. Clinical and subclinical reactivations of varicella-zoster in immunocompromised patients. *J Infect Dis* 1986; 153:840-7.
- Meyers JD, Flournoy N, Thomas ED. Cell-mediated immunity to varicella-zoster virus after allogeneic marrow transplant. *J Infect Dis* 1980;141:479-87.
- Locksley RM, Flournoy N, Sullivan KM, Meyers JD. Infection with varicella-zoster virus after bone marrow transplantation. *J Infect Dis* 1985;152:1172-81.
- Colebunders R, Mann JM, Francis H, Bila K, Izaley L, Ilwaya M, et al. Herpes zoster in African patients: a clinical predictor of

- human immunodeficiency virus infections. *J Infect Dis* 1988; 157:314-8.
36. Friedman-Kien AE, Lafleur FL, Gendler E, Hennessey NP, Montagna R, Halbert S, et al. Herpes zoster: a possible early clinical sign for development of acquired immunodeficiency syndrome in high-risk individuals. *J Am Acad Dermatol* 1986;14:1023-8.
 37. Jacobson MA, Berger TG, Fikrig S, Becherer P, Moohr JW, Stanat SC, et al. Acyclovir-resistant varicella zoster infection after chronic oral acyclovir therapy in patients with the acquired immunodeficiency syndrome (AIDS). *Ann Intern Med* 1990; 112:187-91.
 38. Cohen PR, Beltrani VP, Grossman ME. Disseminated herpes zoster in patients with human immunodeficiency virus infection. *Am J Med* 1988;84:1076-80.
 39. Linnemann CC Jr, Biron KK, Hoppenjans WG, Solinger AM. Emergence of acyclovir-resistant varicella zoster virus in an AIDS patient on prolonged acyclovir therapy. *AIDS* 1990;4: 577-9.
 40. LeBoit PE, Limova M, Yen TS, Palefsky JM, White CR Jr, Berger TG. Chronic verrucous varicella-zoster virus infection in patients with the acquired immunodeficiency syndrome (AIDS): histologic and molecular biologic findings. *Am J Dermatopathol* 1992;14:1-5.
 41. Gilson IH, Barnett JH, Conant MA, Laskin OL, Williams J, Jones PG. Disseminated ecthymatous herpes varicella-zoster infection in patients with acquired immunodeficiency syndrome. *J Am Acad Dermatol* 1989;20:637-42.
 42. Hoppenjans WB, Bibler MR, Orme RL, Solinger AM. Prolonged cutaneous herpes zoster in acquired immunodeficiency syndrome. *Arch Dermatol* 1990;126:1048-50.
 43. Alessi E, Cusini M, Zerboni R, Cavicchini S, Uberti-Foppa C, Galli M. Unusual varicella zoster virus infection in patients with the acquired immunodeficiency syndrome [letter]. *Arch Dermatol* 1988;124:1011-3.
 44. Ragozzino MW, Melton LJ III, Kurland LT, Chu CP, Perry HO. Risk of cancer after herpes zoster: a population-based study. *N Engl J Med* 1982;307:393-7.
 45. Whitney RJ. Varicella-zoster virus infections. In: Galasso GJ, Whitley RJ, Merigan TC, editors. *Antiviral agents and viral diseases of man*. New York: Raven Press; 1990. p. 235.
 46. Melish ME. Bullous varicella: its association with the staphylococcal scalded-skin syndrome. *J Pediatr* 1973;83:1019-21.
 47. McKendall RR, Klawans HL. Nervous system complications of varicella-zoster virus. In: Vinken PJ, Bruyn GW, editors. *Handbook of clinical neurology*; vol 34. Amsterdam: Elsevier; 1978. p. 161.
 48. Krugman S, Goodrich CH, Ward R. Primary varicella pneumonia. *N Engl J Med* 1957;257:843-8.
 49. Weber DM, Pellicchia JA. Varicella pneumonia: study of prevalence in adult men. *JAMA* 1965;192:572-7.
 50. Paryani SG, Arvin AM. Intrauterine infection with varicella-zoster virus after maternal varicella. *N Engl J Med* 1986;314:1542-6.
 51. Whitley RJ, Soong SJ, Dolin R, Betts R, Linnemann C Jr, Alford CA Jr. Early vidarabine therapy to control the complication of herpes zoster in immunosuppressed patients. *N Engl J Med* 1982;307:971-5.
 52. Lewis GW. Zoster sine herpete. *Br Med J* 1958;2:418-21.
 53. Ragozzino MW, Melton LJ III, Kurland LT, Chu CP, Perry HO. Population-based study of herpes zoster and its sequelae. *Medicine (Baltimore)* 1982;61:310-6.
 54. Hope-Simpson RE. The nature of herpes zoster: a long-term study and a new hypothesis. *Proc R Soc Med* 1965;58:9-20.
 55. Kanski JJ. *Clinical ophthalmology*. 2nd ed. London: Butterworth-Heinemann; 1989. p. 101.
 56. McCormick WF, Rodnitzky RL, Schochet SS Jr, McKee AP. Varicella zoster encephalomyelitis. *Arch Neurol* 1969;21:559-70.
 57. Gold E, Robbins FC. Isolation of herpes zoster virus from spinal fluid of a patient. *Virology* 1958;6:293.
 58. Appelbaum E, Kreps SI, Sunshine A. Herpes zoster encephalitis. *Am J Med* 1962;32:25-31.
 59. Norris FH Jr, Leonards R, Calanchini PR, Calder CD. Herpes zoster meningoencephalitis. *J Infect Dis* 1970;122:335-8.
 60. Jemsek J, Greenberg SB, Taber L, Harvey D, Gershon A, Couch RB. Herpes zoster-associated encephalitis: clinicopathologic report of 12 cases and review of the literature. *Medicine* 1983;62:81-97.
 61. Christie AB. *Chickenpox (varicella), herpes zoster, infectious diseases: epidemiology and clinical practice*. 3rd ed. Edinburgh: Churchill-Livingstone; 1980. p. 262, 278.
 62. Juel-Hensen BE, MacCallum FO. *Herpes simplex, varicella, and zoster*. Philadelphia: JB Lippincott; 1972. p. 78-85.
 63. Grant BD, Rowe CR. Motor paralysis of the extremities in herpes zoster. *J Bone Joint Surg [Am]* 1961;43A:885-96.
 64. Thomas JE, Howard FM. Segmented zoster paresis: a disease profile. *Neurology* 1972;22:459-66.
 65. Oberg C, Svedmyr A. Varicelliform eruption in herpes zoster: some clinical and serological observations. *Scand J Infect Dis* 1969;1:47-9.
 66. Glesby MJ, Moore RD, Chaisson RE. Clinical spectrum of herpes zoster in adults infected with human immunodeficiency virus. *Clin Infect Dis* 1995;21:370-5.
 67. Forster DJ, Dugel PV, Frangieh GT, Liggett PE, Rao NA. Rapidly progressive outer retinal necrosis in the acquired immunodeficiency syndrome. *Am J Ophthalmol* 1990;110:341-8.
 68. Sellitti TP, Huang AJW, Schiffman J, Davis JL. Association of herpes zoster ophthalmicus with acquired immunodeficiency syndrome and acute retinal necrosis. *Am J Ophthalmol* 1993; 116:297-301.
 69. Takahashi M. Herpesviridae: varicella zoster virus. In: Lennette EM, Halonen P, Murphy FA, editors. *Laboratory diagnosis of infectious diseases: principles and practice*; vol 2: viral, rickettsial, and chlamydial diseases. New York: Springer-Verlag; 1988. p. 261-75.
 70. Schmidt NJ, Gallo D, Delvin V, Woodie JD, Emmons RW. Direct immunofluorescence staining for detection of herpes simplex and varicella zoster virus antigen in vesicular lesions and certain tissue specimens. *J Clin Microbiol* 1980;12:651-5.
 71. Koropchak CM, Graham G, Palmer J, Winsberg M, Ting SF, Wallace M, et al. Investigation of varicella-zoster virus infection by polymerase chain reaction in the immunocompetent host with acute varicella. *J Infect Dis* 1991;163:1016-22.
 72. Weller TH. Varicella and herpes zoster. In: Lennette EH, Schmidt NJ, editors. *Diagnostic procedures for viral, rickettsial, and chlamydial infections*. 5th ed. Washington (DC): American Public Health Association; 1979. p. 375-88.
 73. Gilden DH, Hayward AR, Krupp J, Hunter-Laszlo M, Huff JC, Vafai A. Varicella-zoster virus infection of human mononuclear cells. *Virus Res* 1987;7:117-29.
 74. Nahass GT, Goldstein BA, Zhu WY, Serfling U, Penneys NS, Leonardi CL. Comparison of Tzanck smear, viral culture, and DNA diagnostic methods in detection of herpes simplex and varicella-zoster infection. *JAMA* 1992;268:2541-4.
 75. Wesselhoeft C. The differential diagnosis of chickenpox and small pox. *N Engl J Med* 1944;230:15.
 76. Gershon AA. Varicella zoster virus. In: Feigin RD, Cherry JD, editors. *Textbook of pediatric infectious diseases*. 4th ed. Philadelphia: WB Saunders; 1998. p. 1769-77.
 77. Lichtenstein PK, Heubi JE, Daugherty CC, Farrell MK, Sokol RJ, Rothbaum RJ. Grade I Reye's syndrome: a frequent cause of

- vomiting and liver dysfunction after varicella and upper-respiratory-tract infection. *N Engl J Med* 1983;309:133-9.
78. Fulginiti VA, Brunell PA, Cherry JD, Ector WL, Gershon AA, Gotoff SP. Aspirin and Reye syndrome. *Pediatrics* 1982;69:810-2.
 79. Dunkel LM, Arvin AM, Whitley RJ, Rotbart HA, Feder HM, Jr, Feldman S, et al. A controlled trial of acyclovir for chickenpox in normal children. *N Engl J Med* 1983;309:133-9.
 80. Prober CG, Kirk LE, Keeney RE. Acyclovir therapy of chickenpox in immunosuppressed children: a collaborative study. *J Pediatr* 1982;101:622-5.
 81. Nyerges G, Meszner Z, Gyarmati E, Kerpel-Fronius S. Acyclovir prevents dissemination of varicella in immunocompromised children. *J Infect Dis* 1988;157:309-13.
 82. Whitley RJ, Hilty M, Haynes R, Bryson Y, Connor JD, Soong SJ, et al. Vidarabine therapy of varicella in immunosuppressed patients. *J Pediatr* 1982;101:125-31.
 83. Arvin AM, Kushner JH, Feldman S, Baehner RL, Hammond D, Merigan TC. Human leukocyte interferon in the treatment of varicella in children with cancer. *N Engl J Med* 1982;306:761-5.
 84. Whitley RJ, Gnann JW. Acyclovir: a decade later. *N Engl J Med* 1992;327:782-9.
 85. Nyerges G, Meszner Z. Treatment of chickenpox in immunosuppressed children. *Am J Med* 1988;85(suppl 2A):94-5.
 86. McGregor RS, Zitelli BJ, Urbach AH, Malatack JJ, Gartner JC Jr. Varicella in pediatric orthotopic liver transplant recipients. *Pediatrics* 1989;83:256-61.
 87. Whitley RJ. Therapeutic approaches to varicella-zoster virus infection. *J Infect Dis* 1992;166(suppl 1):S51-S57.
 88. Varicella-zoster immune globulin for the prevention of chickenpox. *MMWR* 1984;33:84-90, 95-9.
 89. White CJ, Kuter BJ, Hildebrand CS, Isganitis KL, Matthews H, Miller WJ, et al. Varicella vaccine (VARIVAX) in healthy children and adolescents: results from clinical trials, 1987 to 1989. *Pediatrics* 1991;87:604-10.
 90. Gershon AA. Viral vaccines of the future. *Pediatr Clin North Am* 1990;37:689-707.
 91. Gershon AA. Live attenuated varicella vaccine. *Annu Rev Med* 1987;38:41-50.
 92. Guess HA, Broughton DD, Melton LJ III, Kurland LT. Epidemiology of herpes zoster in children and adolescents: a population-based study. *Pediatrics* 1985;76:512-7.
 93. Izurieta HS, Strelbel PM, Blake PA. Post licensure effectiveness of varicella vaccine during an outbreak in a child care center. *JAMA* 1997;278:1495-9.
 94. Lieu TA, Cochi SL, Black SB, Halloran ME, Shinefield HR, Holmes SJ, et al. Cost-effectiveness of a routine varicella vaccination program for US children. *JAMA* 1994;271:375-87.
 95. Juel-Hensen BE, MacCallum FO, Mackenzie AM, Pike MC. Treatment of zoster with idoxuridine dimethyl sulfoxide: results of two double-blind controlled trials. *BMJ* 1970;4:776-80.
 96. Wildenhoff KE, Ipsen J, Esmann V, Ingemann-Jensen J, Poulsen JH. Treatment of herpes zoster with idoxuridine ointment including a multivariate analysis of signs and symptoms. *Scand J Infect Dis* 1979;11:1-9.
 97. Wildenhoff KE, Esmann V, Ipsen J, Harving H, Peterslund NA, Schonheyder H. Treatment of trigeminal and thoracic zoster with idoxuridine. *Scand J Infect Dis* 1981;13:257-62.
 98. Whitley RJ, Chien LT, Dolin R, Galasso GJ, Alford CA, Jr. Adenosine arabinoside therapy of herpes zoster in the immunosuppressed. *N Engl J Med* 1976;294:1193-9.
 99. Whitley RJ, Gnann JW Jr, Hinthorn D, Liu C, Pollard RB, Hayden F, et al. Disseminated herpes zoster in the immunocompromised host: a comparative trial of acyclovir and vidarabine. *J Infect Dis* 1992;165:450-5.
 100. Derse D, Cheng YC, Furman PA, St Clair MH, Elion GB. Inhibition of purified human and herpes simplex virus-induced DNA polymerases by 9-(2-hydroxy-ethoxymethyl) guanine triphosphate. *J Biol Chem* 1981;256:11447-51.
 101. Peterslund NA, Ipsen J, Schonheyder H, Seyer-Hansen K, Esmann V, Juhl H. Acyclovir in herpes zoster. *Lancet* 1981;2:827-30.
 102. Bean B, Braun C, Balfour HH Jr. Acyclovir therapy for acute herpes zoster. *Lancet* 1982;2:118-21.
 103. van den Broek PJ, van der Meer JW, Mulder JD, Versteeg J, Mattie H. Limited value to acyclovir in the treatment of uncomplicated herpes zoster: a placebo-controlled study. *Infection* 1984;12:338-41.
 104. McGill J, MacDonald DR, Fall C, McKendrick GD, Copplestone A. Intravenous acyclovir in acute herpes zoster infection. *J Infect* 1983;6:157-61.
 105. Huff JC, Bean B, Balfour HH Jr, Laskin OL, Connor JD, Corey L, et al. Therapy of herpes zoster with oral acyclovir. *Am J Med* 1988;85(suppl 2A):84-7.
 106. Wood MJ, Ogan PH, McKendrick MW, Care CD, McGill JI, Webb EM. Efficacy of oral acyclovir in the treatment of acute herpes zoster. *Am J Med* 1988;85(suppl 2A):79-83.
 107. Morton P, Thomson AN. Oral acyclovir in the treatment of herpes zoster in general practice. *N Z Med J* 1989;102:93-5.
 108. Harding SP, Porter SM. Oral acyclovir in herpes zoster ophthalmicus. *Curr Eye Res* 1991;10:177-82.
 109. Huff JC, Drucker JL, Clemmer A, Laskin OL, Connor JD, Bryson YJ, et al. Efficacy of oral acyclovir on pain resolution in herpes zoster: a reanalysis. *J Med Virol* 1993;suppl 1:93-6.
 110. Crooks RT, Jones DA, Fiddian AP. Zoster-associated chronic pain: an overview of clinical trials with acyclovir. *Scand J Infect* 1991;suppl 78:62-8.
 111. Sasadeusz JJ, Sachs SL. Systemic antivirals in herpesvirus infections. *Dermatol Ther* 1993;11:171-85.
 112. Burnette TC, de Miranda P. Metabolic disposition of the acyclovir prodrug valaciclovir in the rat. *Drug Metab Dispos* 1994;22:60-4.
 113. de Miranda P, Burnette TC. Metabolic fate and pharmacokinetics of the acyclovir prodrug valaciclovir in cynomolgus monkeys. *Drug Metab Dispos* 1994;22:55-9.
 114. Beutner KR, Friedman DJ, Forszpaniak C, Andersen PL, Wood MJ. Valaciclovir compared with acyclovir for improved therapy for herpes zoster in immunocompetent adults. *Antimicrob Agents Chemother* 1995;39:1546-53.
 115. Beutner K. Antivirals in the treatment of pain. *J Geriatr Dermatol* 1994;(suppl 2)6:23A-28A.
 116. Jacobson MA, Gallant J, Wang LH, Coakley D, Weller S, Gary D, et al. Phase-1 trial of valaciclovir, the L-valyl ester of acyclovir, in patients with advanced human immunodeficiency disease. *Antimicrob Agents Chemother* 1994;38:1534-40.
 117. Earnshaw DW, Vere Hodge RA. Effective inhibition of herpesvirus DNA synthesis by (S)-penciclovir-triphosphate [abstract 1701]. American Society for Microbiology, 32nd Interscience Conference on Antimicrobial Agents and Chemotherapy. Anaheim, Calif, Oct 11-14, 1992.
 118. Pue MA, Pratt SK, Fairless AJ. Linear pharmacokinetics of penciclovir following administration of single oral doses of famciclovir 125, 250, 500 and 750 mg to healthy volunteers. *J Antimicrob Chemother* 1994;33:119-27.
 119. Degreef H, Famciclovir Herpes Zoster Clinical Study Group. Famciclovir, a new oral antiherpes drug: results of the first controlled clinical study demonstrating its efficacy and safety in the treatment of uncomplicated herpes zoster in immunocompetent patients. *Int J Antimicrob Agents* 1994;4:241-6.
 120. Tyring S, Barbarash RA, Nahlik JE, Cunningham A, Marley J, Heng M, et al. Famciclovir for the treatment of acute herpes zoster: effects on acute disease and postherpetic neuralgia. *Ann Intern Med* 1995;123:89-96.

121. Tyring SK, Ring J, Lassonde M, Martel A, Van Slycken S, Crann R, et al. Famciclovir for the treatment of ophthalmic herpes zoster. Presented at the 38th Annual Interscience Conference on Antimicrobial Agents and Chemotherapy, San Diego, Calif, Sept 24-27, 1998.
122. Machida H. Comparison of susceptibilities of varicella-zoster virus and herpes simplex viruses to nucleoside analogs. *Antimicrob Agents Chemother* 1986;29:524-6.
123. Bodsworth N J, Boag F, Burdge D, Genereux M, Borleffs JCC, Evans BA, et al. Evaluation of sorivudine (BV-araU) versus acyclovir in the treatment of acute localized herpes zoster in human immunodeficiency virus-infected adults. *J Infect Dis* 1997;176:103-11.
124. Yan J, Tyring SK, McCrary ML, Lee PC, Haworth S, Raymond R, et al. The effect of sorivudine on dihydropyrimidine dehydrogenase activity in patients with acute herpes zoster. *Clin Pharmacol Ther* 1997;61:563-73.
125. Gnann JW, Crumpacker CS, Lalezari JP, Smith JA, Tyring SK, Baum KF, et al. Sorivudine versus acyclovir for treatment of dermatomal herpes zoster in human immunodeficiency virus-infected patients: results from a randomized, controlled clinical trial. *Antimicrob Agents Chemother* 1998;42:1139-45.
126. Gnann JW. New antivirals with activity against varicella-zoster virus. *Ann Neurol* 1994;35(suppl):S69-72.
127. Söltz-Szöts J, Tyring S, Anderson PL, Lucht F, McKendrick MW, Dial Perez JL, et al. A randomized controlled trial of acyclovir versus netivudine for treatment of herpes zoster. *J Antimicrob Chemother* 1998;41:549-56.
128. Wills RJ, Dennis S, Spiegel HE, Gibson DM, Nadler PI. Interferon kinetics and adverse reactions after intravenous, intramuscular, and subcutaneous injection. *Clin Pharmacol Ther* 1984;35:722-7.
129. Eaglstein WH, Katy R, Brown JA. The effects of early corticosteroid therapy on the skin eruption and pain of herpes zoster. *JAMA* 1970;211:1681-3.
130. Post B, Philbrick JT. Do corticosteroids prevent postherpetic neuralgia? A review of the evidence. *J Am Acad Dermatol* 1988;18:605-10.
131. Wood MJ, Johnson RW, McKendrick MW, Taylor J, Mandal BK, Crooks J. A randomized trial of acyclovir for 7 days or 21 days with and without prednisolone for treatment of acute herpes zoster. *N Engl J Med* 1994;330:896-900.
132. Whitley RJ, Weiss H, Gnann JW, Tyring S, Mertz GJ, Pappas PG, et al. Acyclovir with and without prednisone for the treatment of herpes zoster. *Ann Intern Med* 1996;125:376-83.
133. Safrin S, Assaykeen T, Follansbee S, Mills J. Foscarnet therapy for acyclovir-resistant mucocutaneous herpes simplex virus infection in 26 AIDS patients: preliminary data. *J Infect Dis* 1990;161:1078-84.
134. Wahren B, Oberg B. Reversible inhibition of cytomegalovirus replication by phosphonoformate. *Intervirology* 1980;14:7-15.
135. Tyring SK. Advances in antiviral therapy and prophylaxis in dermatology. Presented at the 56th Annual Meeting, American Academy of Dermatology, Orlando, Fla, Feb 27-March 4, 1998.
136. Swerdlow M. Anticonvulsant drugs and chronic pain. *Clin Neuropharmacol* 1982;7:51-82.
137. Swerdlow M. The treatment of shooting pain. *Postgrad Med J* 1980;56:159-61.
138. Killian JM, Fromm GH. Carbamazepine in the treatment of neuralgia. *Arch Neurol* 1968;19:129-36.
139. Rowbotham M, Harden N, Stacey B, Bernstein P, Magnus-Miller L. Gabapentin for the treatment of postherpetic neuralgia. *JAMA* 1998;280:1837-42.
140. Taylor JC. Trigeminal neuralgia treated with G.32883. *J Neurol Neurosurg Psychiatry* 1963;26:553-4.
141. Nathan PW. Chlorprothixene (Taractan) in post-herpetic neuralgia and other severe chronic pain. *Pain* 1978;5:367-71.
142. Tenicela R, Lovasik D, Eaglstein W. Treatment of herpes zoster with sympathetic blocks. *Clin J Pain* 1985;1:63-7.
143. Suzuki H, Ogawa S, Nakagawa H, Kanayama T, Tai K, Saitoh H, et al. Cryocautery of sensitized skin areas for the relief of pain due to postherpetic neuralgia. *Pain* 1980;9:355-62.
144. Colding A. The effect of sympathetic blocks on herpes zoster. *Acta Anaesthesiol Scand* 1969;13:133-41.
145. Colding A. Treatment of pain: organization of a pain clinic: treatment of acute herpes zoster. *Proc R Soc Med* 1973;66:541-3.
146. Rowbotham MC, Fields HL. Topical lidocaine reduces pain in post-herpetic neuralgia. *Pain* 1989;38:297-301.
147. Kissin J, McDanal J, Xavier AV. Topical lidocaine for relief of superficial pain in postherpetic neuralgia. *Neurology* 1989;39:1132-3.
148. Stow PJ, Glynn CJ, Minor B. EMLA cream in the treatment of post-herpetic neuralgia: efficacy and pharmacokinetic profile. *Pain* 1989;39:301-5.
149. Nathan PW, Wall PD. Treatment of post-herpetic neuralgia by prolonged electric stimulation. *Br Med J* 1974;3:645-7.
150. Bernstein JE, Korman NJ, Bickers DR, Dahl MV, Millikan LE. Topical capsaicin treatment of chronic postherpetic neuralgia. *J Am Acad Dermatol* 1989;21:265-70.
151. Watson CPN, Evans RJ, Watt VR. Postherpetic neuralgia and topical capsaicin. *Pain* 1988;33:333-40.
152. Tindall GT, Odam GL, Vieth RG. Surgical treatment of postherpetic neuralgia: results of skin undermining and excision in 14 patients. *Arch Neurol* 1962;7:423-6.
153. Weidman MJ. Surgical relief of post-herpetic pain by excision of scarred skin. *Med J Aust* 1976;63:472-3.
154. Friedman AH, Nashold BS. DREZ lesions for postherpetic neuralgia. *Neurosurgery* 1984;15:969-70.
155. Bowsheer D. The management of postherpetic neuralgia. *Postgrad Med J* 1996;73:623-9.
156. Watson CP, Evans RJ, Reed K, Merskey H, Goldsmith L, Warsh J. Amitriptyline versus placebo in postherpetic neuralgia. *Neurology* 1982;32:671-3.
157. Watson CP, Chipman M, Reed K, Evans RJ, Birkett N. Amitriptyline versus maprotiline in postherpetic neuralgia: a randomized, double-blind, crossover trial. *Pain* 1992;48:29-36.
158. Kishore-Kumar R, Max MB, Schafer SC, Gaughan AM, Smoller B, Gracely RH, et al. Desipramine relieves postherpetic neuralgia. *Clin Pharmacol Ther* 1990;47:305-12.
159. Watson CP, Evans RJ. A comparative trial of amitriptyline and zimeclidine in postherpetic neuralgia. *Pain* 1985;23:387-94.
160. Takahachi M. Current status and prospects of live varicella vaccine. *Vaccine* 1992;10:1007-14.
161. Hardy I, Gershon AA, Steinberg SP, LaRussa P. The incidence of zoster after immunization with live attenuated varicella vaccine. *N Engl J Med* 1991;325:1545-50.
162. Liang MG, Heidelberg KA, Jacobson RM, McEvoy MT. Herpes zoster after varicella immunization. *J Am Acad Dermatol* 1998;38:761-3.
163. Hayward A, Villaneuba E, Cosyns M, Levin M. Varicella-zoster virus (VZV) specific cytotoxicity after immunization of nonimmune adults with OKA strain attenuated VZV vaccine. *J Infect Dis* 1992;166:260-4.
164. Levin MJ, Murray M, Zerbe GO, White CJ, Hayward AR. Immune responses of elderly persons 4 years after receiving a live attenuated varicella vaccine. *J Infect Dis* 1994;170:522-6.
165. Zerboni L, Nader S, Aoki K, Arvin AM. Analysis of the persistence of humoral and cellular immunity in children and adults immunized with varicella vaccine. *J Infect Dis* 1998;177:1701-4.

166. Perren TJ, Powles RL, Easton D, Stolle K, Selby RJ. Prevention of herpes zoster in patients by long-term oral acyclovir after allogeneic bone marrow transplantation. *Am J Med* 1988; 85(suppl 2A):99-101.
167. Pahwa S, Biron K, Lim W, Swenson P, Kaplan MH, Sadick N. Continuous varicella-zoster infection associated with acyclovir resistance in a child with AIDS. *JAMA* 1988;260:2879-82.
168. Safrin S, Berger TG, Gilson I, Wolfe PR, Wofsy CB, Mills J, et al. Foscarnet therapy in five patients with AIDS and acyclovir-resistant varicella zoster virus infection. *Ann Intern Med* 1991;115:19-21.

Answers to CME examination

Identification No. 899-106

June 1999 issue of the Journal of the American Academy of Dermatology

Questions 1-31, Landau M, Krafchik BR. *J Am Acad Dermatol* 1999;40:877-90.

- | | |
|------|------------|
| 1. c | 17.b |
| 2. c | 18.c |
| 3. b | 19.a |
| 4. a | 20.e |
| 5. b | 21.d |
| 6. b | 22.a |
| 7. b | 23.c |
| 8. a | 24.e |
| 9. a | 25.d |
| 10.a | 26.b |
| 11.b | 27.c |
| 12.b | 28.a |
| 13.b | 29.b |
| 14.a | 30.d |
| 15.b | 31.a, c, e |
| 16.a | |

CME examination

Identification No. 899-107

Instructions for Category I CME credit appear in the front advertising section. See last page of Contents for page number.

Questions 1-30: McCrary ML, Severson J, Tyring SK. J Am Acad Dermatol 1999;41:1-14.

Directions for questions 1-20: Give single best response.

- The incidence of shingles in a person with a history of varicella infection is
 - 10%
 - 20%
 - 30%
 - 40%
 - 50%
- At what point in time does the secondary viremia of varicella infection infect the epidermis?
 - 2 to 4 days
 - 4 to 6 days
 - 6 to 8 days
 - 10 to 14 days
 - 14 to 16 days
- The highest incidence of herpes zoster is seen among cancer patients with
 - lung cancer
 - breast cancer
 - colon cancer
 - Hodgkin's disease
 - prostate cancer
- The most common extracutaneous complication of varicella zoster virus (VZV) infection is
 - central nervous system
 - cardiovascular
 - genitourinary
 - musculoskeletal
 - lymphoreticular
- The pain preceding the onset of shingles typically occurs how many days before the onset of the rash?
 - 1 to 3
 - 3 to 5
 - 5 to 7
 - 7 to 10
 - 10 to 14
- Each of the following is commonly seen with maternal infection with VZV in the first trimester *except*
 - cicatricial skin lesions
 - hypoplastic limbs
 - hypertelorism
 - cortical atrophy
 - low birth weight
- The percentage of patients with herpes zoster who experience pain in the involved dermatome before the development of the rash is
 - 50%
 - 60%
 - 70%
 - 80%
 - 90%
- Postherpetic neuralgia affects what percentage of patients with herpes zoster who are older than 60 years of age?
 - 10% to 15%
 - 20%
 - 30%
 - 40%
 - 50%
- Ramsay Hunt syndrome can be associated with herpes zoster and each of the following *except*
 - ipsilateral facial palsy
 - vesicles on the external ear
 - chorioretinitis
 - tinnitus
 - deafness
- Ophthalmic zoster is complicated by ocular disease in what percentage of patients?
 - 1%
 - 10% to 20%
 - 20% to 70%
 - 30% to 50%
 - More than 90%
- Ocular manifestations of herpes zoster commonly include each of the following *except*
 - keratitis
 - cataracts
 - uveitis
 - scleritis
 - secondary glaucoma
- Motor paralysis occurs in what percentage of patients with herpes zoster?
 - 1% to 5%
 - 5% to 10%
 - 10% to 15%
 - 15% to 20%
 - 20% to 30%

13. The most common central nervous system finding with herpes zoster is
 - a. facial paralysis
 - b. motor paralysis
 - c. granulomatous cerebral angiitis
 - d. cerebrospinal fluid abnormalities
 - e. meningitis
 14. A few vesicles can be found remote from the primarily affected dermatome in approximately what percentage of immunocompetent patients?
 - a. 5% to 10%
 - b. 10% to 20%
 - c. 20% to 40%
 - d. 40% to 60%
 - e. 60% to 70%
 15. The risk of dissemination in immunocompromised patients with herpes zoster can be estimated at what percentage?
 - a. 10%
 - b. 20%
 - c. 40%
 - d. 60%
 - e. 80%
 16. Each of the following can be used as a stain for a Tzanck smear *except*
 - a. hematoxylin-and-eosin
 - b. Giemsa
 - c. Wright
 - d. periodic acid-Schiff
 - e. Papanicolaou
 17. The efficacy of the VZV vaccine (in terms of seroconversion) is estimated to be more than what percentage?
 - a. 50%
 - b. 60%
 - c. 70%
 - d. 80%
 - e. 90%
 18. Myelosuppression occurs if sorivudine is given in conjunction with
 - a. cytoxan
 - b. 5-fluorouracil
 - c. cyclosporine
 - d. imuran
 - e. methotrexate
 19. For strains of herpes simplex or herpes zoster found to be resistant to acyclovir, the most appropriate therapy is
 - a. foscarnet
 - b. valaciclovir
 - c. famciclovir
 - d. vidarabine
 - e. idoxuridine
 20. The modality that is probably of greatest benefit in the treatment of postherpetic neuralgia is
 - a. EMLA cream
 - b. anticonvulsants
 - c. narcotics
 - d. tricyclic antidepressants
 - e. serotonin reuptake inhibitors
- Directions for questions 21-30: For each numbered item, choose the appropriate lettered item.*
- a. True
 - b. False
21. Herpes is an RNA virus.
 22. Shingles can be acquired by direct contact with varicella lesions.
 23. Immunocompromised patients with VZV infection are most likely to have lung, liver, and central nervous system involvement.
 24. Herpes zoster can be diagnosed in the absence of a rash.
 25. The rash of herpes zoster is most likely to be in the area that was most severely affected by varicella.
 26. VZV can be distinguished from herpes simplex virus by a Tzanck smear.
 27. Acyclovir has been shown to decrease the duration and severity of varicella.
 28. Both valaciclovir and famciclovir have been shown to reduce the duration of acute pain associated with zoster.
 29. Acyclovir must first be phosphorylated by cellular thymidine kinase.
 30. Acyclovir is useful in the prevention of postherpetic neuralgia.